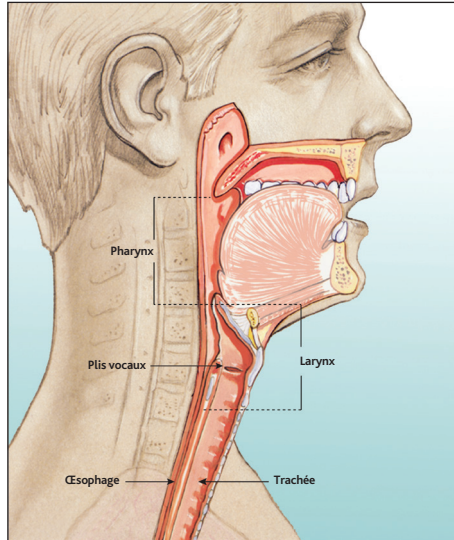
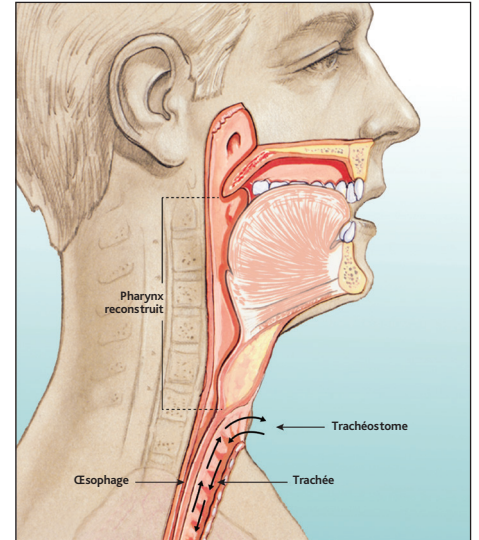


# Modifications anatomiques après laryngectomie totale et méthodes de réhabilitation phonatoire

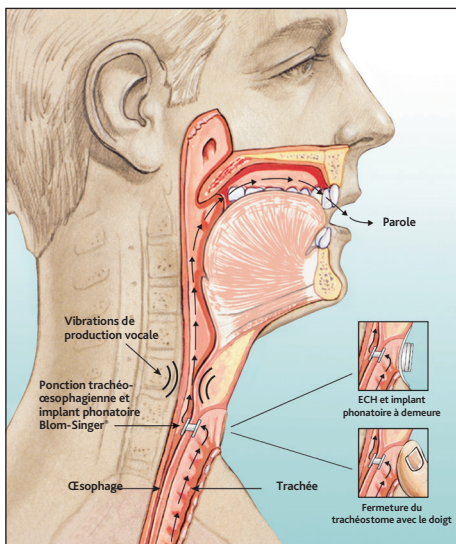
**Blom-Singer®**  
 La voix de l'expérience depuis 1978



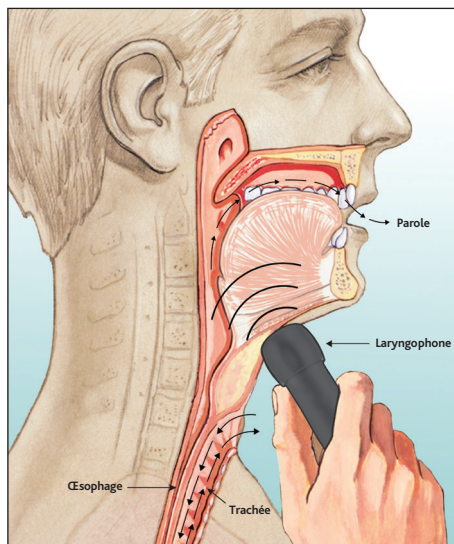
Avant la laryngectomie totale



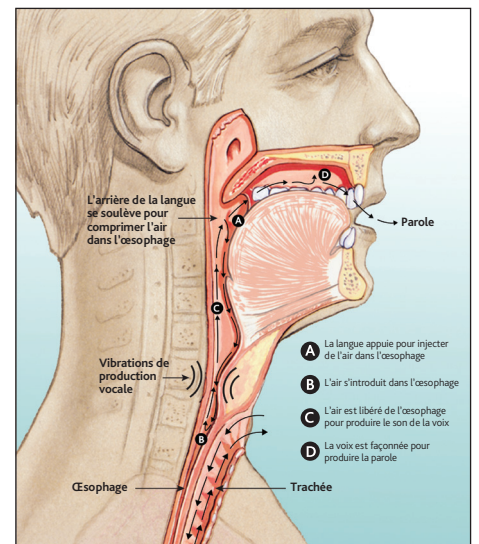
Après la laryngectomie totale



Implant phonatoire trachéo-oesophagien



Laryngophone



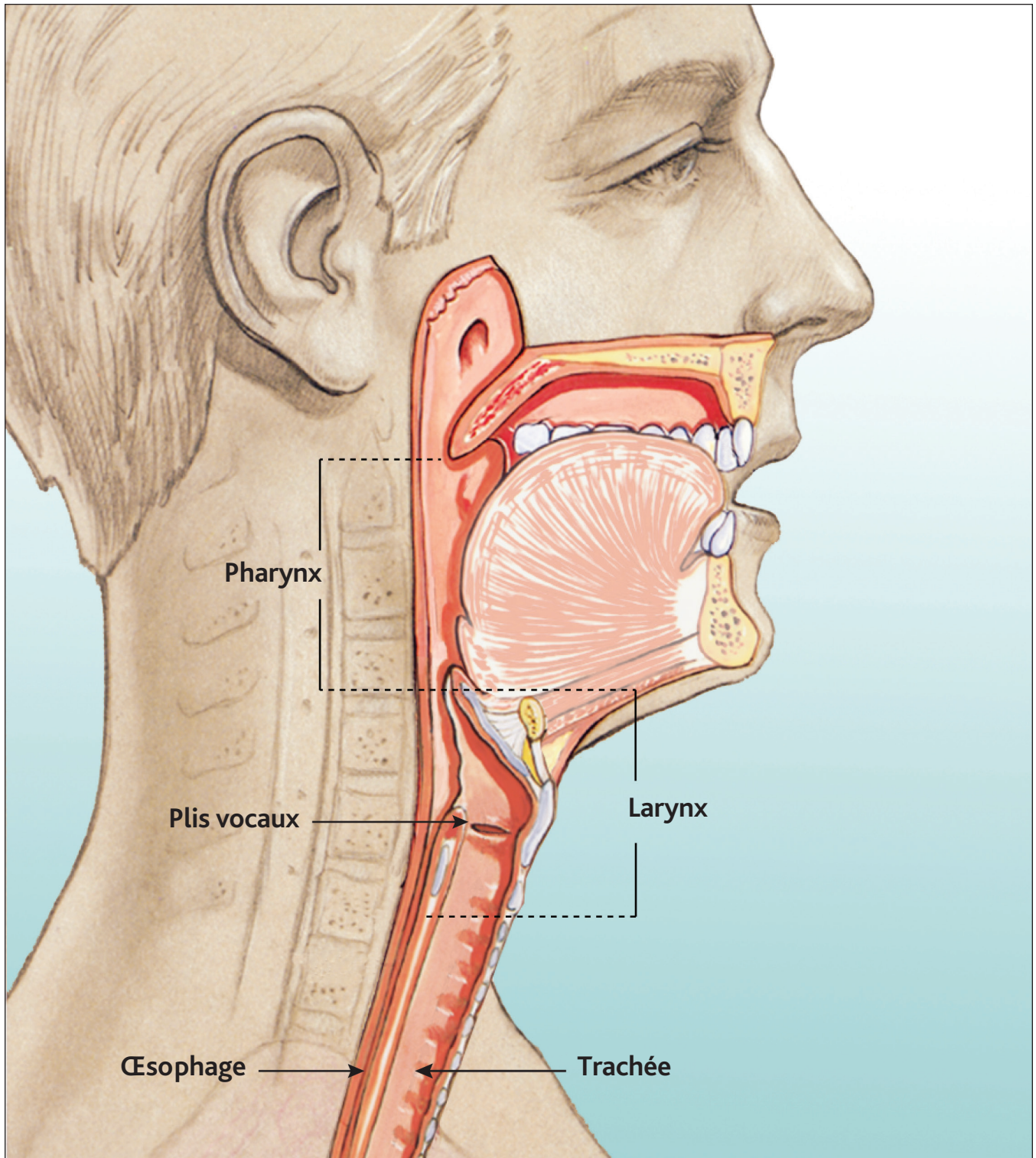
Voix oro-oesophagienne

**INHEALTH®**  
 TECHNOLOGIES

*We speak ENT*

[www.inhealth.com](http://www.inhealth.com)

# Avant la laryngectomie totale



Remarques:

---

---

---

---

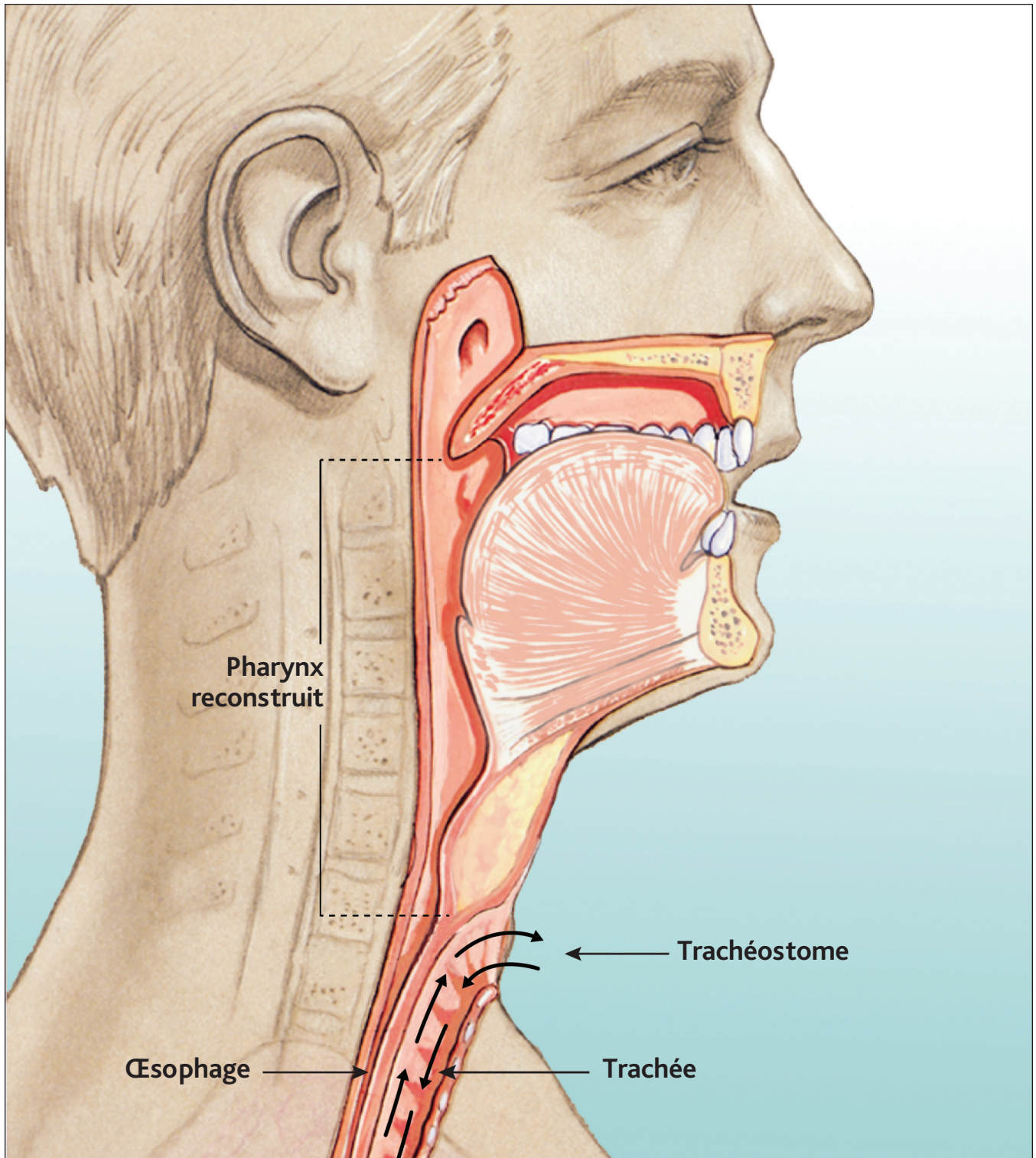
---

**INHEALTH**<sup>®</sup>  
TECHNOLOGIES

**Blom-Singer**<sup>®</sup>



# Après la laryngectomie totale



Remarques:

---

---

---

---

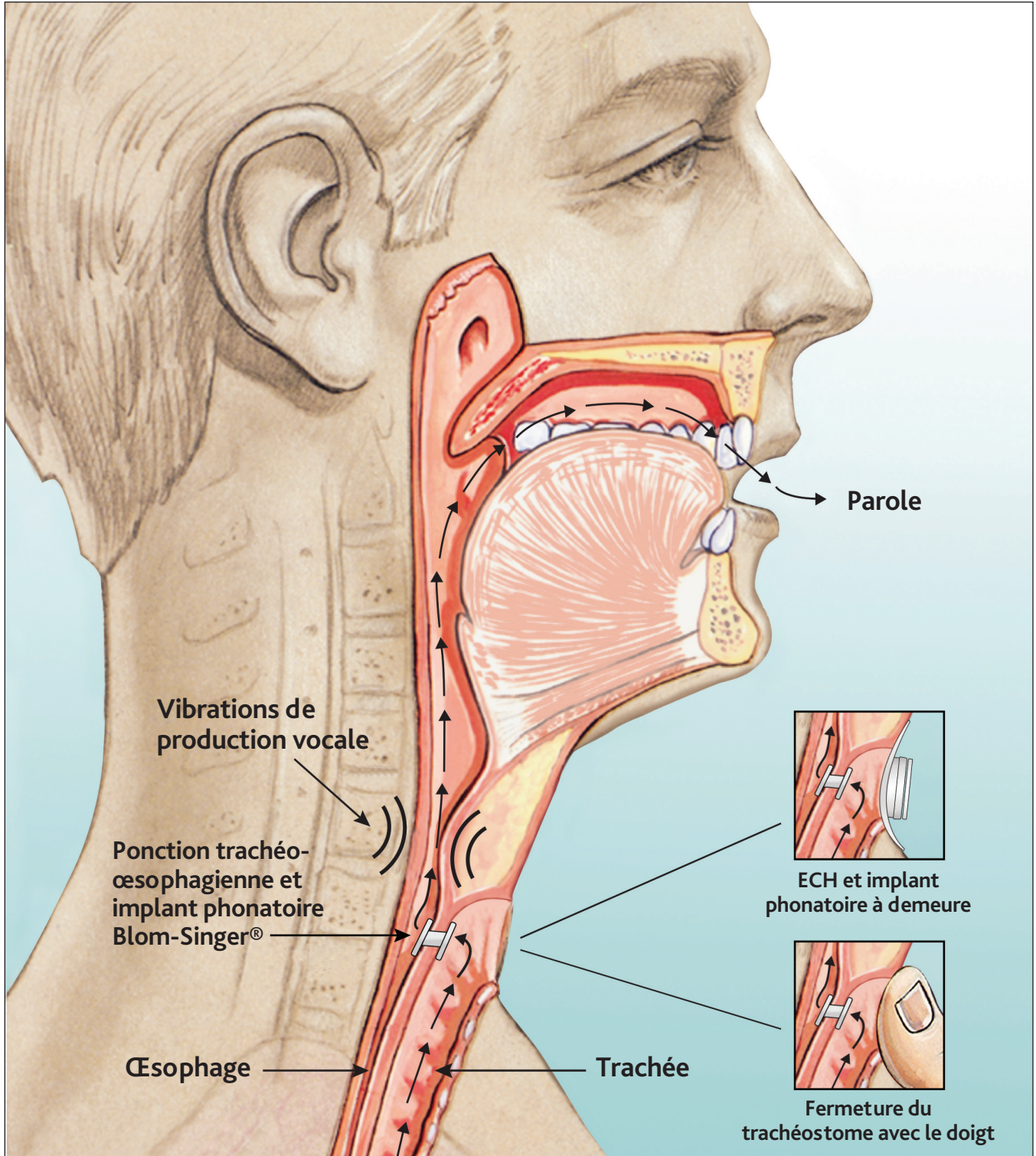
---

**INHEALTH**<sup>®</sup>  
TECHNOLOGIES

**Blom-Singer**<sup>®</sup>



# Implant phonatoire trachéo-oesophagien



Remarques:

---

---

---

---

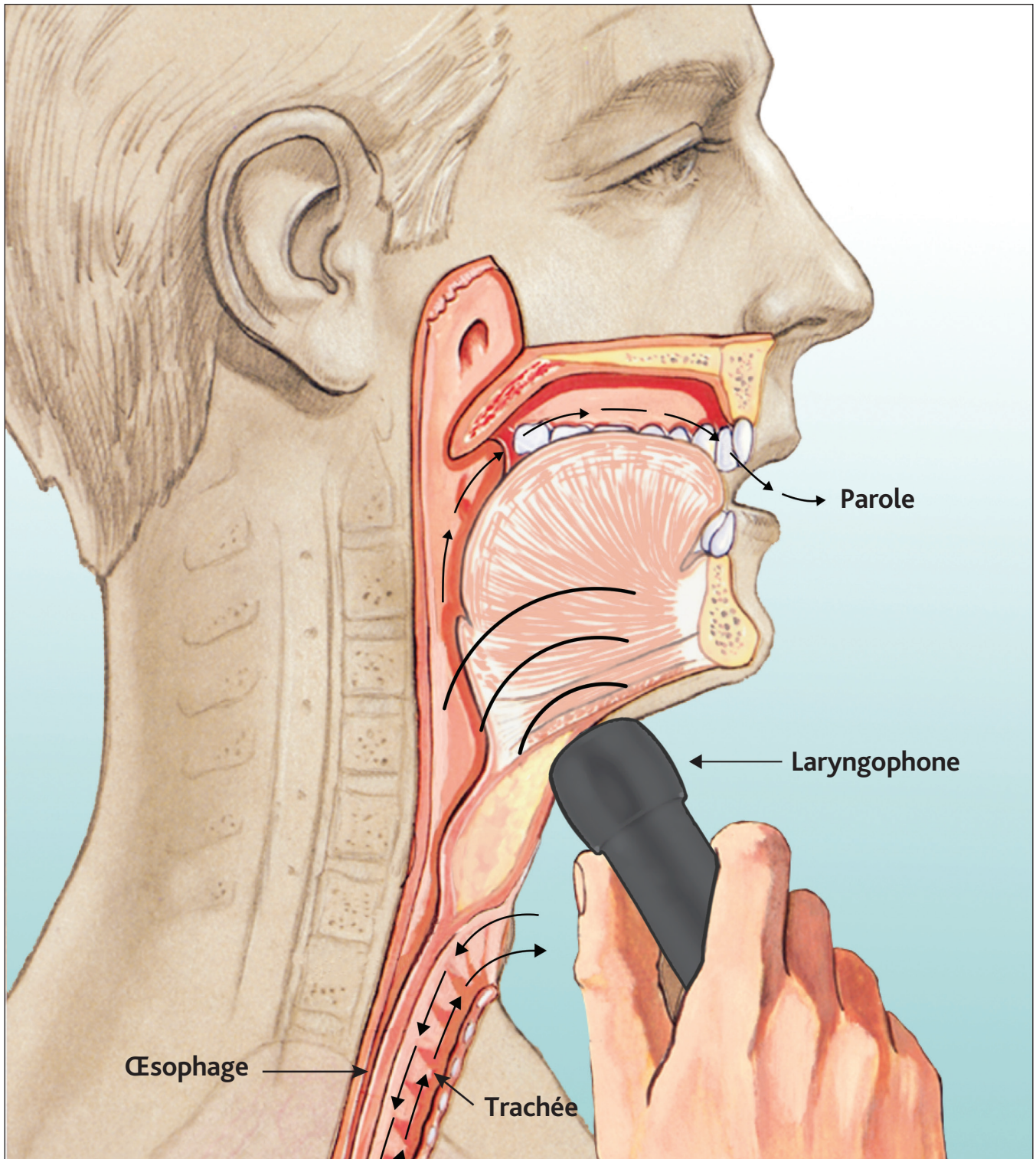
---

**INHEALTH**<sup>®</sup>  
TECHNOLOGIES

**Blom-Singer**<sup>®</sup>



# Laryngophone



Remarques:

---

---

---

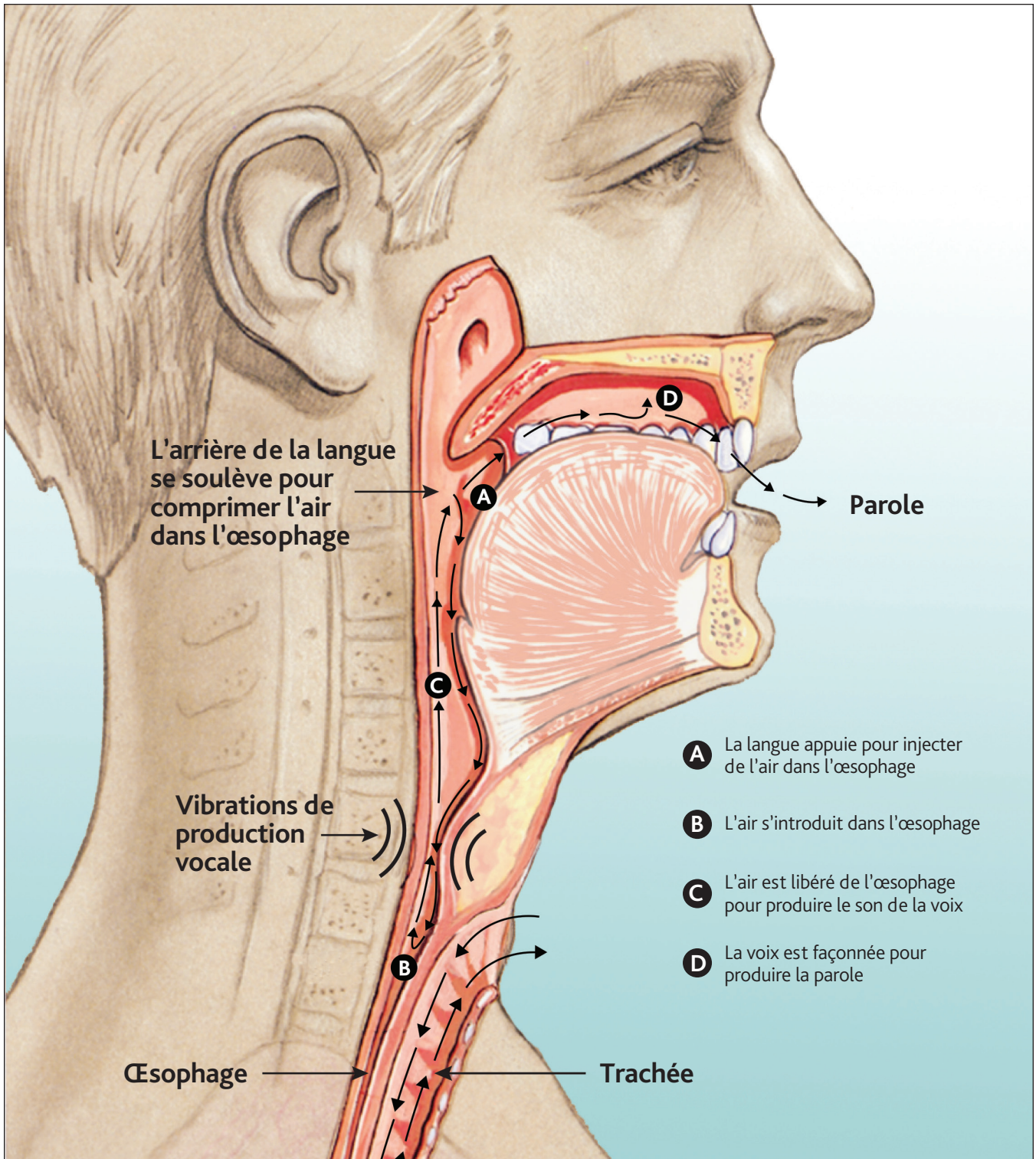
---

**INHEALTH**<sup>®</sup>  
TECHNOLOGIES

**Blom-Singer**<sup>®</sup>



# Voix oro-œsophagienne



Remarques:

---

---

---

---

---

**INHEALTH**<sup>®</sup>  
TECHNOLOGIES

**Blom-Singer**<sup>®</sup>